Last update: April 2024

Uterine fibroids (uterine leiomyoma)

Author: Dr. med. Susanne Lanz

Oberärztin, Fachärztin für Gynäkologie und Geburtshilfe, Schwerpunkt operative Gynäkologie und Geburtshilfe, speziell Myomsprechstunde, Dysplasie, minimalinvasive Chirurgie, Universitätsklinik für Frauenheilkunde, Inselspital Bern

Co-Author(s): Prof. Dr. med. Michel Mueller

Introduction

Uterine fibroids are the most common benign tumors in women. Not all fibroids cause symptoms, but depending on their location, size and number, they can lead to bleeding disorders, pain or pressure pain and have a negative impact on fertility. Although they consist of benign tissue, they cause considerable morbidity worldwide and continue to be the most common indication for hysterectomy in our part of the world. Women of child-bearing age are most frequently affected. Fibroids can be single or multiple, and they can measure just a few millimeters or fill the whole abdomen, weighing several kilograms.

They grow expansively. Large nodes or multiple fibroids can cause dysfunction by increasing pressure on their surroundings (neighboring organs or the uterus itself), for example hydronephrosis due to ureter compression.

Definition

Many common synonyms:

- Myoma = Uterine Fibroma = "Fibroid" = Uterine Leiomyoma

Fibroids are benign uterine tumors that grow from the smooth muscle of the uterine wall (thus technically leiomyoma). The neoplasm(s) generally grow as ‘knots’, and are more rarely diffuse. Fibroids grow at different speeds. Several fibroids exposed to the same hormonal environment in the same uterus can display very different patterns of growth. Connective tissue also proliferates to different degrees. The connective tissue gives the rough texture of the fibroid.

- Uterine corpus fibroids are much more common than cervical fibroids (only 5 %).
- Uterus myomatosus (myomatous uterus) expansion of the uterus due to one or more fibroid nodes, often growing to several times the original size.

FIGO staging

Fibroids are classified according to their location within the uterine wall. This nomenclature is designed to simplify the uniform description of fibroids and is helpful for treatment planning.

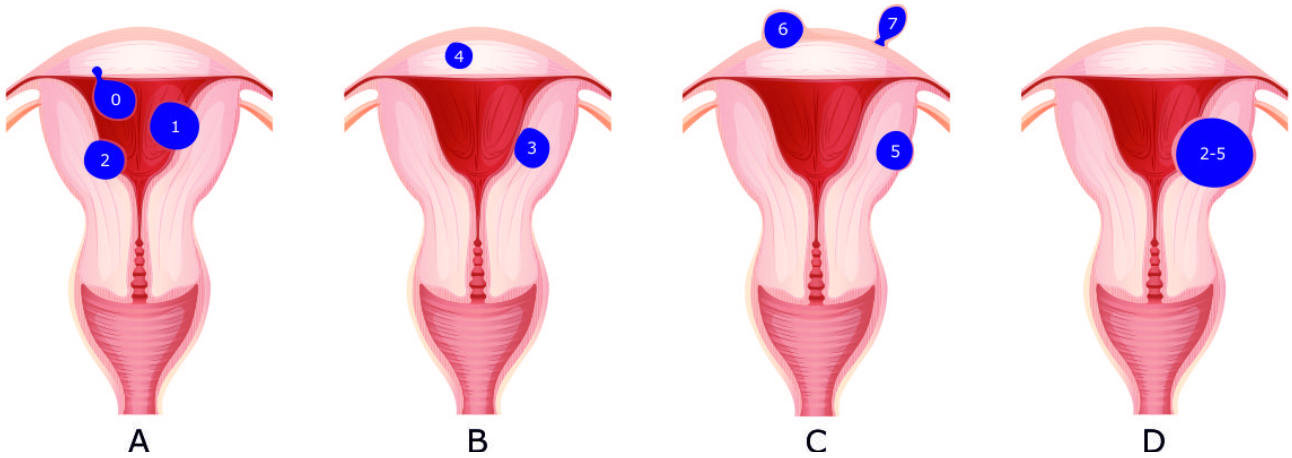

Illustration 1: Locations and directions of proliferation.
A – Submucosal leiomyoma (FIGO 0, 1, 2), B – Intramural leiomyoma (FIGO 3, 4), C – Subserosal leiomyoma (FIGO 5, 6, 7), D – Hybrid leiomyoma

- FIGO 0: Pedunculated intracavitary
- FIGO 1: < 50 % intramural
- FIGO 2: ≥ 50 % intramural
- FIGO 3: Contacts endometrium, 100 % intramural

- FIGO 4: intramural
- FIGO 5: subserosal ≥ 50 % intramural
- FIGO 6: subserosal < 50 % intramural
- FIGO 7: subserosal pedunculated
- FIGO 8: others live e.g. cervical; parasitic

According to the location and direction of proliferation, a distinction is drawn between:

Submucosal leiomyoma (FIGO 0, 1, 2)

Growth begins directly under the endometrium, protruding to different extents towards the uterine cavity. The covering endometrium is often hypotrophic. Quickly lead to symptoms, in particular heavy menstrual bleeding. If these fibroids become pedunculated and grow into the cavity, they can be pushed towards the cervix and vagina by uterine contractions (nascent fibroids).

Intramural leiomyoma (FIGO 3, 4)

Fibroids most often grow within the uterine wall. As they grow, they can cause the wall between the endometrium and the serosa to expand several times over.

Subserosal leiomyoma (FIGO 5, 6, 7)

Proliferation close to the surface of the uterus. Subserosal fibroids cause the serosa to visibly protrude. If a fibroid originates directly below the serosa, a stalk can form as it increases in size (pedunculated subserosal fibroid, FIGO type 7).
If the fibroid is in a lateral position, it may protrude towards the broad ligament of the uterus (intraligamentary parametrial fibroid). Growth of the fibroid can lead to compression of the ureter, blood vessels or nerves.

Transmural (hybrid) leiomyoma (FIGO 2-5)

Fibroids that take up the whole uterine wall and push the endometrium inwards and the serosa outwards are classified as type 2-5.

Special cases (FIGO 8)

Specific fibroids that do not fit the aforementioned categories, such as cervical or parasitic leiomyomas, are classified as FIGO 8. Parasitic fibroids: this is the term used to describe fibroids that originate in small fragments of fibroid tissue. Such fragments can remain in the abdomen after morcellation of fibroids in laproscopic myomectomyUnder favorable conditions, these fragments can attach to tissue (e.g. peritoneum) and grow into independent tumors without any contact to the uterus.

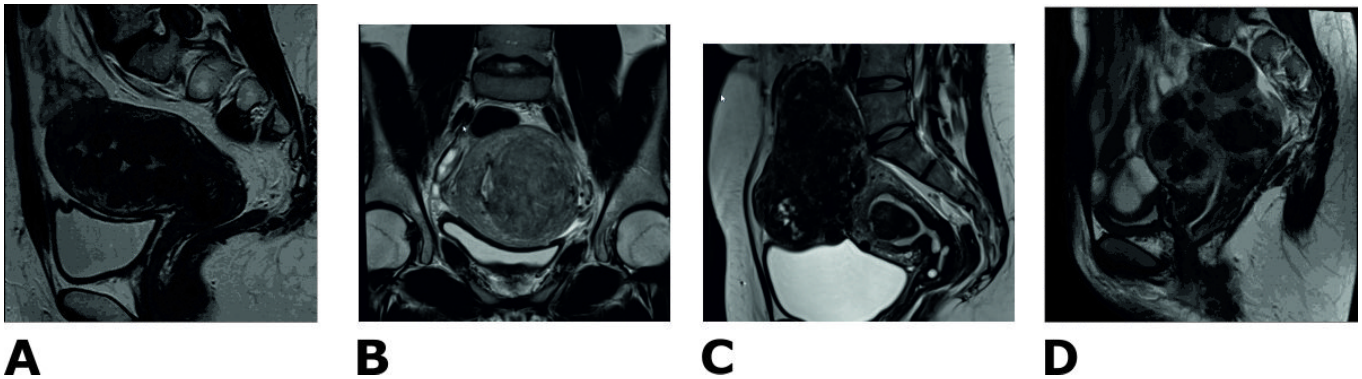

Illustration 2: MRI examples.
A – Multiple submucosal leiomyoma (FIGO 0, 1, 2) (sagittal section)
B – Transmural leiomyoma (FIGO 2-5) (coronal section)
C – Intracavity (FIGO 0) and large subserosal (FIGO 6) leiomyomas (sagittal section)
D – Multiple intramural (FIGO 3,4) and subserosal (FIGO 5,6) leiomyomas (sagittal section)

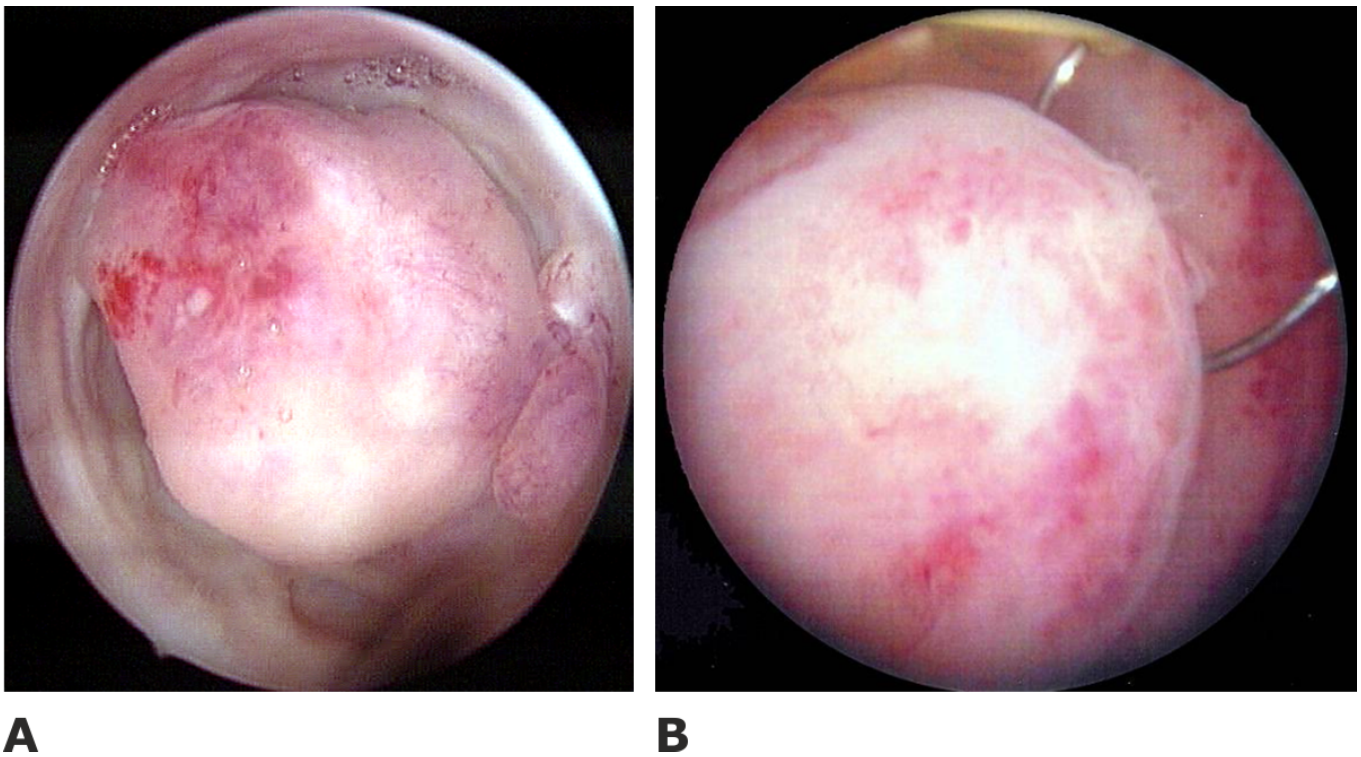

Figure 3: A – Hysteroscopy with submucosal fibroid Type O, B – Hysteroscopy with submucosal fibroid Type I

Epidemiology

- Approximately 80 % of fibroids occur between 30 and 50 years of age. Fibroids can be found in approximately 70 % of all women aged 40 or more, if targeted microscopic (fibroid up to 5 mm) investigations are carried out. However, only 15 to 25 % of these fibroids are symptomatic.
- Fibroids are often multiple.
- They generally stagnate or improve after menopause (regression, calcification) - unless postmenopausal hormone replacement therapy is used, for example.

Etiopathogenesis

The most important risk factor for uterine fibroids is race: compared to light-skinned women, African American women are 3x more affected, Hispanic women 2x more. Other risk factors include older age (about 60 % African American women 35-49 years with fibroids, versus 80 % > 50 years), hypertension, obesity, vitamin D deficiency, exposure to endocrine disrupting chemicals (EDC). The familial clustering suggests a genetic predisposition (e.g. polymorphisms in the gene that codes for COMT (catechol-O-methyltransferase)).
A great deal of scientific work is being invested in deciphering the complex pathogenesis of fibroids. This much is known so far:
A normal myometrial stem cell becomes a so-called TIC, a tumor initiating cell, through DNA damage, DNA driver mutations and epigenetic changes under the influence of inflammatory factors (cytokines, interleukins), growth factors and hormones, which then proliferates into abnormally differentiated myoma cells. An altered genital microbiome is also discussed as a favoring factor. The growth of fibroids can be characterized by abnormal cell proliferation, excessive deposition of extracellular matrix (collagen fibronectin), inhibited apoptosis and DNA instability.

EDC

“endocrine disrupting chemicals” are substances that occur in the environment, in food or articles of daily use and that interfere with hormone biosynthesis, metabolism or action. They are absorbed into the body by inhalation, ingestion or transdermally. For example, parabens (found in sunscreen, lipstick, depilatory creams and many other cosmetics), phthalates (floor coverings, paints, films, cables, nail varnish, etc.) or bisphenol A (toys, baby bottles, plastic tableware, etc.). EDCs are metabolized in the body and excreted in the urine. By measuring the metabolites in the urine, conclusions can be drawn about the exposure to the respective EDC.

EDCs can promote the transformation of a myoma stem cell into a TIC, but they can also have a direct effect on the myoma cells and stimulate proliferation, inflammation and fibrosis and inhibit apoptosis.

As various cosmetics that are used almost exclusively by dark-skinned women (skin lighteners, “hair relaxers” for hair straightening) are particularly contaminated with EDCs, they are also discussed as being partly responsible for the disproportionate incidence of fibroids in this population.

Clinical morphology

Histopathology shows the interior of fibroid nodes as whorl-like. The outer muscle layer of the fibroid and the surrounding myometrium are often concentric, leading to a pseudocapsule. When cut, fibroids appear white. Secondary signs of degeneration are necrosis, bleeding, fibrosis, calcification, myxoid degeneration.

Clinical picture

Fibroids do not necessarily cause symptoms. Epidemiological studies show that only approx. 25 % of fibroids lead to symptoms that require treatment.

The type and extent of symptoms depend on the location (FIGO type) and size of the fibroid.

Bleeding disorders (e. g. excessively heavy bleeding with clots, metrorrhagia or prolonged bleeding) are found in half of fibroid patients - particularly those with submucosal or transmural fibroids. Significant iron deficiency anemia is possible!

Location and size dictate the symptoms of fibroid. The main symptom is often a bleeding disorder (such as heavy or prolonged menstrual bleeding, metrorrhagia). In addition, approx. 30 % of fibroid patients experience pain.

- This is usually localized stretching or pressure pain due to the tumor mass(es).
- Secondary dysmenorrhea (with metrorrhagia) is often observed with submucosal fibroids.
- Cramp-like pains can be caused by uterine contractions as a reaction to the fibroid as a “foreign body”.
- Acute peritoneal symptoms including acute abdomen occur with twisted pedunculated subserosal fibroids or with fibroid necrosis.

Symptoms as a result of pressure on surroundings structures (such as the bladder, ureter, intestine or blood vessels) are rare, but possible for various organ systems (for example taking the form of renal congestion, constipation, constant urge to urinate or urinary retention, impaired venous flow from legs with potential thrombus formation).

Fibroids and fertility

Several studies have shown that submucosal fibroids reduce fertility and that removing these submucosal fibroids under appropriate care improves fertility.

No impact on fertility has been clearly shown for either intramural or subserosal fibroids. However, it should be noted that there are only a few prospective randomized studies that have investigated this issue. The studies available are mostly retrospective and have a very different study design. Intramural fibroids larger than 4 cm and causing uterine cavity distortion may impact fertility. Many authors therefore think that intramural fibroids > 4 cm should be removed before fertility treatments.

If intracavity (particularly pedunculated) fibroids necrotize, this can lead to inflammation, bleeding and malodorous vaginal discharge.

Fibroids very rarely develop into leiomyosarcomas. Various genetic studies have shown that fibroids and leiomyosarcomas have different origins and leiomyosarcomas.

Diagnosis

Diagnosis is based on history, physical examination and vaginal ultrasound. This triad of methods is sufficient in 90 % of cases for differentiating uterine fibroids from adnexal masses of unknown origin.

Transvaginal ultrasound is the imaging method of choice. This can generally diagnose, delimit and measure fibroids reliably, as well as providing good follow-up control of the size. The typical ultrasound image shows a hypoechoic round or oval mass, potentially with a whorled interior and often acoustic attenuation or calcifications. Vascularization is typically predominantly found as a net-like structure on the surface of the fibroid. It is not possible to fully exclude sarcoma on ultrasound.

If a submucosal fibroid is suspected, a suitable additional examination, which is also available in practice, is sonohysterography (the uterine cavity is filled with sterile saline via a thin catheter inserted across the cervix, so that the distended cavity is anechoic and visibility of the extent of fibroid protrusion towards the cavity is optimal). 3D ultrasound also allows a very good assessment of submucosal fibroids

Hysteroscopy is a more costly but often worthwhile option. This offers a clear differentiation between submucosal fibroids and uterine polyps, for example, and is often combined directly with resection or curettage in the clarification procedure for bleeding of unknown origin or cycle length disorders.

In exceptional cases, where differential diagnosis is challenging, other imaging methods may be used, including computer tomography (CT), intravenous pyelogram (IVP) or magnetic resonance imaging (MRI).

With multiple fibroids, a pre-operative MRI is often logical and helpful for precise planning of treatment. For example, for deciding whether a myomectomy can be carried out laparoscopically or whether a laparotomy is required, or which fibroids can be treated with radiofrequency ablation.
If ultrasound or MRI are unable to clarify whether a finding is malignant, a pre-operative PET-CT should be carried out, as sensitivity for sarcoma diagnosis is much higher with PET than MRI.

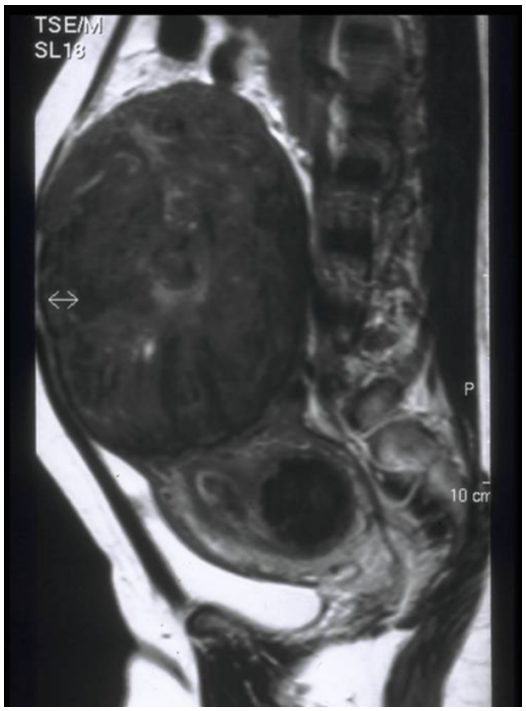

Figure 5: MRI with evidence of subserosal and intramural fibroids.

A diagnostic laparoscopy is sometimes carried out - as any uncertainty as to whether there is also an adnexal mass must be clarified!

Differential diagnosis

DD of nodular masses in lower abdomen:

- Adnexal mass (neoplasia, endometriosis, tubo-ovarian abscess)
- Adenomyosis
- Severely retroverted/retroflexed uterus
- Uterine malformation (e.g. double uterus)
- Hydrometra, hematometra, pyometra
- Pregnancy
- Intestinal tumors (diverticulitis, peritoneal abscess, carcinoma)
- Retroperitoneal tumors (e.g. spreading from lymphatic system)
- Pelvic kidney (rare)
- Sarcoma (rare)

Progression

Natural progression, potential complications and secondary changes relating to fibroids.

When advising patients on treatment and the urgency of starting treatment, it is useful and important to be able to give a reasonably reliable prognosis on the natural growth pattern of the disease. In view of the undisputed hormonal connection, it is expected that fibroids will start to grow after puberty, continue this growth throughout the reproductive years, then shrink after menopause. However, this is not the case, as consistently shown by studies of fibroid growth using sequential imaging (MRI or ultrasound). Fibroids can show various non-linear and largely unpredictable growth patterns, from spontaneous regression with shrinkage to slow or very fast growth. On average, they grow approx. 9 % every 6 months, but this ranges from -89 % to +138 %. Submucosal fibroids appear to grow more slowly than intramural and subserosal fibroids, and on average fibroids in white women aged over 45 years only grow slowly. Other constant parameters have not been identified. Over time, fibrosis, hyalinosis and calcification can occur, as well as central necrosis and myxoid degeneration in some cases with rapid growth. With pedunculated fibroids, a twisted pedicle can lead to acute hemorrhagic necrosis. Fibroids can also regress fully and spontaneously.

Treatment

The indication for treatment and prioritization of the various options is based on the symptoms (bleeding disorders? pain/pressure pain? infertility? etc.), the number, size and location of fibroids, current lifestyle, patient's wishes (e. g. family planning? secondary diagnosis? surgical pre-procedure? age? avoidance of hormones? avoidance of general anesthetic?) and the treatment objectives. Treatment options range from medication to conservative surgery and interventional radiology procedures to radical surgery in the form of hysterectomy.

- Fibroids with clear clinical symptoms should be removed.
- With asymptomatic uterus myomatosus, regular clinical and vaginal ultrasound check-ups (every 6 to 12 months) may be considered.
- It is often stated that fibroids with "rapid growth" or "clear size progression" should be removed, but there are no uniform definitions of the speed of this growth

Fibroid treatment: A general rule applies treatment is only indicated if symptoms requiring treatment exist (approx. 1/4 cases). Sterility and status post miscarriage/premature birth* are also symptoms.

* In individual cases causality may be difficult to establish. Caution should therefore be applied with regard to an indication for surgery in the context of sterility/infertility. Submucosal and large intramural fibroids can be treated with surgery if necessary.

Drug treatment

Symptomatic, non-hormonal treatment

Heavy menstrual bleeding can be treated with tranexamic acid, perimenstrual administration of NSAIDs, or iron supplements.

Hormonal treatment

Combined contraception administered orally, vaginally or transdermally in the traditional regimen (3 weeks medication, 1 week break with withdrawal bleeding), but above all in a long-term regimen can reduce blood loss.

Progesterone preparations can also reduce bleeding or cause amenorrhea due to their atrophying effect on the endometrium. Slightly higher expulsion rates should be expected with levonorgestrel IUDs (Mirena®) due to uterine deformation caused by fibroids. Parenterally administered long-term progesterones (medroxyprogesterone acetate = Depo Provera®) have a similar effect but more frequently lead to inconvenient metrorrhagia.

These drug-based treatment options regulate the bleeding cycle. They are therefore predominantly used in patients with heavy menstrual bleeding, for example when it is a question of bridging the gap until menopause without carrying out a major procedure.

Causal hormonal treatment

GnRH analogues (11,25 mg leuprorelin or 10,8 mg goserelin (Zoladex LA) injected every 12 weeks) reduce gonadotropins (LH and FSH) and ovarian hormones via pituitary down-regulation, thus leading to amenorrhea and reducing fibroid mass by approx. 40 %. It can be sensible to administer GnRH analogues for 3 to 6 months before surgery in order to achieve better baseline hemoglobin and facilitate a less invasive surgery with less blood loss due to the reduction in fibroid size. They are not suitable as long-term treatment due to the significant adverse effects caused by hypoestrogenism (in particular osteoporosis and menopausal symptoms).

GnRH antagonists

Since 02/2023, the peroral GnRH antagonist Relugolix- CT has been approved in Switzerland under the name Ryeqo® by swissmedic for the treatment of hypermenorrhea in premenopausal women with fibroids.

Composition of Ryeqo®: 40 mg relugolix, 1 mg estradiol, 0,5 mg norethisterone acetate

The GnRH receptors in the anterior pituitary gland are blocked by Relugolix, FSH and LH are suppressed and the production of estrogen and progesterone in the ovary is suppressed. Thanks to integrated add back therapy, estradiol levels are kept stable at a level corresponding to the early follicular phase, which alleviates the myoma-associated symptoms but preserves bone density and alleviates the vasomotor side effects of hypoestrogenemia.

The studies on efficacy and tolerability currently cover a treatment period of 2 years. At the end of this period, the primary endpoint of the study, namely the response rate, defined as blood loss < 80 ml/mt and reduction in monthly blood loss > 50 % compared to baseline, was achieved in around 70 % of the candidates. 58,5 % of the test subjects had amenorrhea after 2 years of therapy.

Relugolix CT was also significantly superior to placebo in most secondary endpoints (pain, amenorrhea, stress due to bleeding and lower abdominal discomfort, uterine volume, anemia, monthly blood loss).

Compared to GnRH analogs, the GnRH antagonist (without add back) achieved an equivalent improvement in hypermenorrhea more quickly by eliminating the initial flare up effect and the cycle returned to normal more quickly after the end of therapy.

(The selective progesterone receptor modulator (SPRM) ulipristal acetate (Esmya®) was temporarily authorized in Switzerland following enthusiastically received study results concerning bleeding profile and volume reduction versus placebo and GnRH analogues, but has since been removed from the market for the indication of myomas due to rare but very serious hepatic adverse effects.)

Supportive therapies

The role of vitamin D

Vitamin D is synthesized in the skin from sunlight. After hydroxylation in the liver and kidneys, it is transported as 1,25 dihydroxy vitamin D to the target organs, where it docks onto the vitamin D receptor (VDR). Age, climate, sun protection and clothing influence the amount produced. The darker the skin pigmentation, the lower the vitamin D production with the same sunlight exposure. Around 80 % of dark-skinned women have a vitamin D deficiency according to standard values, compared to around 20 % of fair-skinned women. Studies consistently show that vitamin D levels in the serum of myoma patients are significantly lower than in myoma-free control groups, suggesting a link between vitamin D levels and myoma development and growth.

First small intervention studies show encouraging results: Vitamin D administration can reduce fibroid growth and possibly also the risk of recurrent fibroids after myomectomy. Compared to other medical treatments for fibroids, vitamin D is a low-cost option for women trying to conceive and has no limit on duration of use.

Diet

Food products can influence hormone-dependent diseases - including fibroids. However, clear evidence is difficult to generate: the spontaneous growth behavior of fibroids is very variable and different foods probably influence each other. There is relative agreement in the study results that fruit (especially citrus fruits) and vegetables (especially green vegetables) reduce the risk of fibroids, whereas meat and fat increase the risk. The results on dairy products, alcohol, wholegrain products and soy are contradictory.

Green tea plays a special role between nutrition and phytotherapy. Green tea extract, in particular epigallocatechin gallate (EGCG), appears to slow down the growth of fibroids. In vitro, antiangiogenic, antiproliferative, antifibrotic and proapoptotic activities of EGCG on leiomyoma cells have been observed. First studies with myoma patients show promising results, especially when EGCG was combined with vitamin D.

Uterus-preserving invasive methods

Risk of uterine rupture following myomectomy: The risk of uterine rupture during pregnancy does not depend on the chosen access but on the technique used. In the literature, the danger of uterine rupture during subsequent pregnancy following myomectomy is lower than after a Cesarean section, regardless of whether the surgery was laparoscopic or open. In a systematic review, the risk of rupture during birth was 0,47 %, and 1,52 % during pregnancy before birth. It is important that the cavity resulting from fibroid removal is closed correctly, so that there is no post-operative hematoma, and the layers can be adapted correctly. Extensive coagulation should be avoided as much as possible. Intraoperative opening of the uterine cavity increases the risk of intrauterine synechiae and should therefore be avoided wherever possible. However, the risk of uterine rupture is not increased by accidental opening of the uterine cavity, despite persistently circulated statements to the contrary. Various studies have shown that scar formation is complete after three months. Pregnancy can therefore be attempted after this time. Birth after myomectomy does not have to be via Cesarean section. The recommended type of birth should be determined by the surgeon, based on the length, number and location of myomectomy scars.

Fibroid enucleation (generally laparoscopy or hysteroscopy): Treatment option for women who may wish to have (more) children or who wish to keep their uterus (e. g. for patients for whom it is important to keep the uterus for personal reasons).

Fibroid enucleation techniques:

- Submucosal fibroid: Hysteroscopic removal/electroresection with sling. For large fibroids and anemia, preparative treatment with GnRH analogues can take place. Nascent pedunculated submucosal fibroids can - if the connection is clear - be gripped with forceps at the root of the peduncle and then twisted until removal.
- Subserosal fibroid: Mostly removed successfully via laparoscopy. A special cutting instrument (cutting tube/morcellator) is used to remove large fibroids from the abdomen. The fibroid is broken up inside a plastic bag inserted into the abdomen to ensure that no small fragments remain in the body. Any such fragments could, under certain conditions, develop into parasitic fibroids. If there is any suspicion of sarcoma, intra-abdominal fragmentation of the fibroid must be avoided and open surgery must be carried out if necessary.
- Intramural fibroid: Laparoscopic removal with reliable, usually multilayer, careful suturing of the myometrium. Potential pretreatment with GnRH analogues in case of anemia. Potential laparotomy for multiple or large fibroids.

Radiofrequency ablation: For women who wish to keep their uterus and desire minimally invasive fibroid treatment, transcervical US-guided radiofrequency ablation (Sonata®) is a possibility. The fibroid or fibroids are fixed in place with a metal trocar under ultrasound guidance, then exposed to radiofrequency energy via fan-shaped electrodes placed in the fibroid and adapted to its size. The fibroids in the predefined area are then heated to 105 degrees Celsius. The resulting coagulation necrosis causes the fibroids to shrink by up to 70 % of their volume over the following months. If the endometrium is within the ablation area, there is also a rapid improvement in heavy menstrual bleeding. This technique is particularly suited for larger submucosal fibroids type 1 and 2, and transmural fibroids type 2-5. Intramural fibroids type 3, 4 and 5 are also accessible. Fibroids with subserosal sections cannot be fully ablated, as a temperature safety zone must be established around neighboring organs to protect them from heat damage.

Uterine fibroid embolization

- A potential treatment option for individual fibroids.
- A femoral catheter is inserted into the uterine artery under x-ray guidance. It is then placed precisely at each arterial end branch that supplies a fibroid. Insoluble particles are then introduced into this arterial branch via the catheter, leading to embolization. The fibroid shrinks over the following months.
- Risks/complications: General risks associated with catheter procedures; post-embolization syndrome (predominantly nausea, vomiting, pain); accidental infection (potentially after a long latency period - rarely with uterine suppuration --> in some circumstances “still” requiring hysterectomy --> uterine fibroid embolization is therefore not indicated for women who wish to have children!).

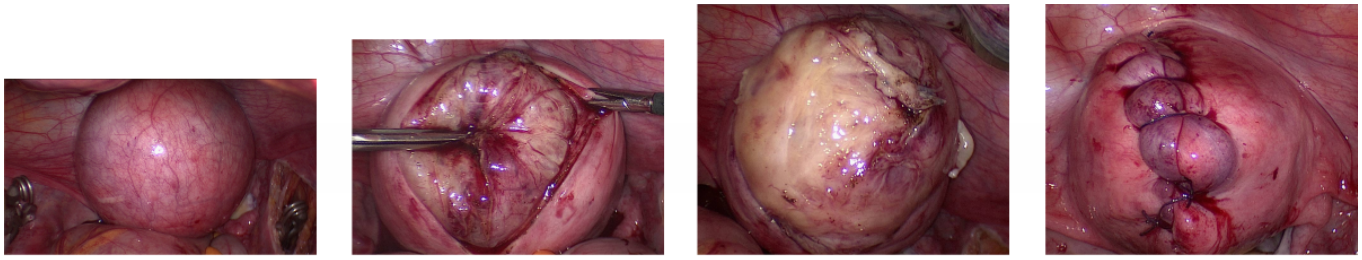

Figure 6: Laparascopic myomectomy - technique
A – Temporary ligature of uterine arteries.
B – Careful, layer-by-layer enucleation of the fibroid.
C – Careful, layer-by-layer enucleation of the fibroid. Very little bleeding due to temporary ligature of uterine arteries.
D – Two-layer suturing of wound cavity, ensuring that layers are adapted correctly.

Hysterectomy

If the patient does not want (more) children and agrees to removal of the uterus, a hysterectomy can be proposed as a definitive solution. It is associated with a much lower morbidity rate than laparoscopic myomectomy, and is usually technically simpler to carry out. Hysterectomy can be carried out vaginally, laparoscopically or via laparotomy. The advantages of vaginal/laparoscopic hysterectomy are shorter hospitalization times and quicker recovery. Vaginal surgery is possible if the uterus can be sufficiently descended.

Fibroids during pregnancy

Although uterine fibroids are very common tumors, and pregnancy with uterus myomatosus is therefore a common phenomenon, statements on the growth patterns of fibroids during pregnancy are not always consistent. Causes for growth and shrinkage are often speculative and not well substantiated.
There is broad consensus concerning the observation that many uterine fibroids gain significant volume in the first trimester, with this growth slowing in the second half of pregnancy. Occasionally, central fibroid necrosis can occur during pregnancy, leading to severe abdominal pain in those affected.

Other fibroid-related pregnancy complications include early miscarriage, anomalies of presentation, growth restriction, premature placental abruption, preterm contractions, PROM, postpartum uterine atony with postpartum hemorrhage, and postpartum sepsis. Depending on their size and location, fibroids can occasionally present an obstacle to vaginal delivery.

Fibroid surgery during pregnancy is associated with increased blood loss and a risk of miscarriage/preterm birth. Myomectomy during Cesarean section is also not recommended due to the high risk of hemorrhage.

Literature

Nr.	Title	Author	Journal	Volume	Pages	Ye
[B01]	The frequency of uterine leiomyomas	Cramer SF, Patel A	Am J Clin Pathol	94	435-438	19
[B02]	High cumulative incidence of uterine leiomyoma in black and white women: ultrasound evidence	Baird DD, Dunson DB et al.	Am J Obstet Gynecol	188	100-107	20
[B03]	Epidemiology of uterine fibroids: a systematic review	Stewart EA, Cookson CL, Gandolfo RA, Schulze-Rath R	BJOG	124(10)	1501-1512	20
[B04]	Treatment of Uterine Fibroid Symptoms with Relugolix Combination Therapy	Al-Hendy A, Lukes AS, Poindexter AN 3rd, Venturella R, Villarroel C, Critchley HOD, Li Y, McKain L, Arjona Ferreira JC, Langenberg AGM, Wagman RB, Stewart EA	N Engl J Med	384(7)	630-642	20

Nr.	Title	Author	Journal	Volume	Pages	Ye
[B05]	Ulipristal acetate versus leuprolide acetate for uterine fibroids	Donnez J, Tomaszewski J et al.	N Engl J Med	366	421-432	20
[B06]	The FAST-EU trial: 12-month clinical outcomes of women after intrauterine sonography-guided transcervical radiofrequency ablation of uterine fibroids	Brölmann H, Bongers M, Garza-Leal JG, Gupta J, Veersema S, Quartero R, Toub D	Gynecol Surg	13	27-35	20
[B07]	Etiology, symptomatology, and diagnosis of uterine myomas	Parker WH	Fertility and Sterility	87, No 4		20
[B08]	Natural History of Uterine Fibroids: A Radiological Perspective	Ghosh S, Naftalin J, Imrie R, Hoo WL	Curr Obstet Gynecol Rep	7(3)	117-121	20
[B09]	Growth trend of small uterine fibroids and human chorionic gonadotropin serum levels in early pregnancy: an observational study	Ciavattini A, Delli Carpini G, Clemente N, Moriconi L, Gentili C, Di Giuseppe J	Fertil Steril	105(5)	1255–1260	20

Nr.	Title	Author	Journal	Volume	Pages	Ye
[B10]	Fibroids and infertility: a systematic review of the evidence	Pritts EA	Obstet Gynecol Surv	56	483-491	20
[B11]	Relugolix combination therapy in Black/ African American women with symptomatic uterine fibroids: LIBERTY Long-Term Extension study	Stewart EA, Al-Hendy A, Lukes AS, Madueke-Laveaux OS, Zhu E, Proehl S, Schulmann T, Marsh EE	Am J Obstet Gynecol	230(2)	237.e1-237.e11	20
[B12]	LIBERTY randomized withdrawal study: relugolix combination therapy for heavy menstrual bleeding associated with uterine fibroids	Al-Hendy A, Venturella R, Arjona Ferreira JC, Li Y, Soulban G, Wagman RB, Lukes AS	Am J Obstet Gynecol	229(6)	662.e1-662.e25	20

Nr.	Title	Author	Journal	Volume	Pages	Ye
[B13]	Treatment of Uterine Fibroid Symptoms with Relugolix Combination Therapy	Al-Hendy A, Lukes AS, Poindexter AN 3rd, Venturella R, Villarroel C, Critchley HOD, Li Y, McKain L, Arjona Ferreira JC, Langenberg AGM, Wagman RB, Stewart EA	N Engl J Med	384(7)	630-642	20
[B14]	Uterine Fibroids and Diet	Tinelli A, Vinciguerra M, Malvasi A, Andjić M, Babović I, Sparić R	Int J Environ Res Public Health	18(3)	1066	20
[B15]	Epigallocatechin Gallate for the Treatment of Benign and Malignant Gynecological Diseases-Focus on Epigenetic Mechanisms	Włodarczyk M, Ciebiera M, Nowicka G, Łoziński T, Ali M, Al-Hendy A	Nutrients	16(4)	559	20

Nr.	Title	Author	Journal	Volume	Pages	Ye
[B16]	A Systematic Review of Vitamin D and Fibroids: Pathophysiology, Prevention, and Treatment	Combs A, Singh B, Nylander E, Islam MS, Nguyen HV, Parra E, Bello A, Segars J	Reprod Sci	30(4)	1049-1064	20

Nr.	Title	Author	Journal	Volume	Pages	Year
[P01]	Risk factors for uterine rupture after laparoscopic Myomectomy	Parker WH, Einarsson J, Istre O, Dubuisson JB	Journal of Minimally Invasive Gynecology	17, No 5		2010
[P02]	Trial of labor after myomectomy and uterine rupture: a systematic review	Gambacorti-Passerini Z, Gimovsky AC, Locatelli A, Berghella V	Acta Obstet Gynecol Scand	95(7)	724-734	2016
[P03]	MRI evaluation of the uterine structure after myomectomy	Tsuji S, Takahashi K, Imaoka I, Sugimura K, Miyazaki K, Noda Y	Gynecol Obstet Invest	61	106-110	2006
[P04]	Evaluation of postmyomectomy uterine scar	Darwish AM, Nasr AM, El-Nashar DA	J Clin Ultrasound	33	181-186	2005